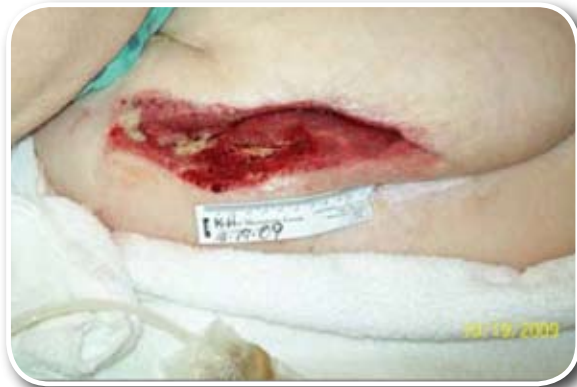
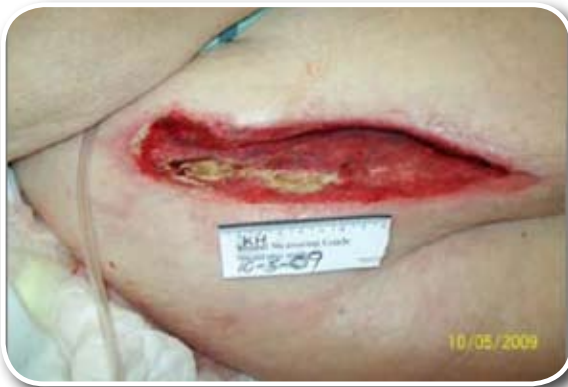
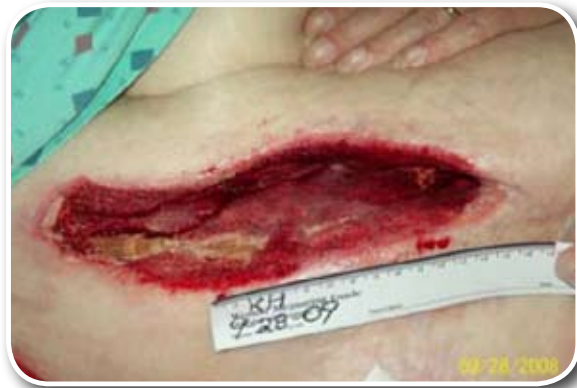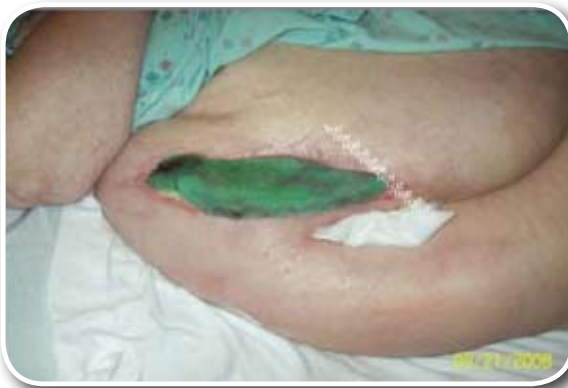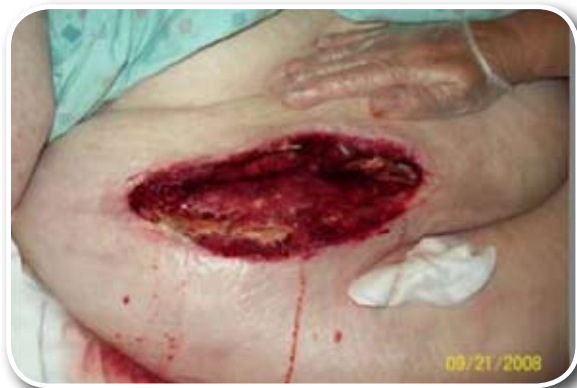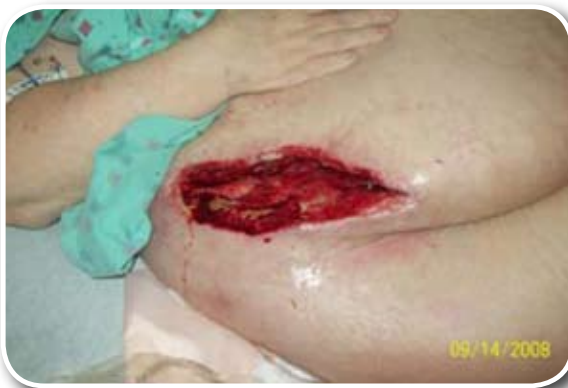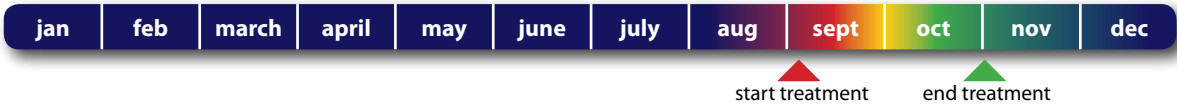CaseStudy

Genadyne A4 and foam to treat a postoperative debridement flank abscess

Michael S. DO, The Wound Healing Center Indianapolis, IN
Cynthia Peebles RN D.O.N., Becky Beck RN Heartland at Prestwick NH Avon, IN

Patient is a 67 year old morbidly obese female who developed a flank abscess requiring aggressive debridement. Postoperatively, therapy was commenced using the Genadyne A4 pump and foam at 80mmHg. Using this therapy, rapid improvements were noted. Despite dramatic decreases in all wound dimensions, the patient's overall condition worsened with progressive malnutrition and immobility. Approximately two weeks after the last picture, she succumbed to her multiple co-morbidities. The wound had decreased from 19x5x7 cm to 15x3x4 cm.



A more detail and complete list of case studies can be presented upon request.

Genadyne Biotechnologies
65 Watermill Lane | Great Neck | NY 11021 | U.S.A
Tel.: +1-516-487-8787 Fax: +1-516-487-7878
E-mail: npwt@genadyne.com | www.genadyne.com

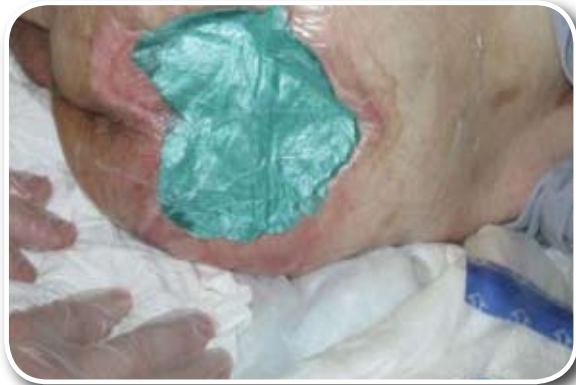
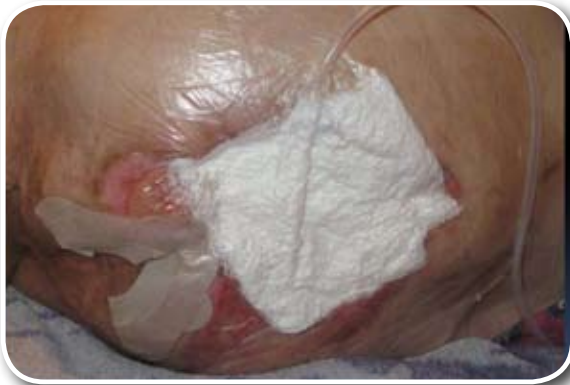
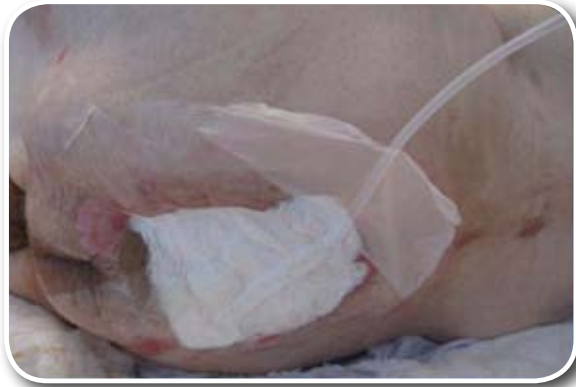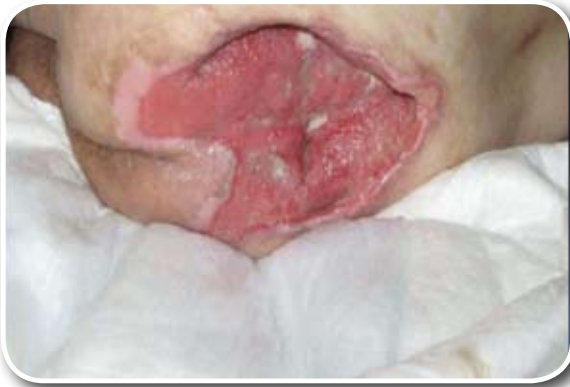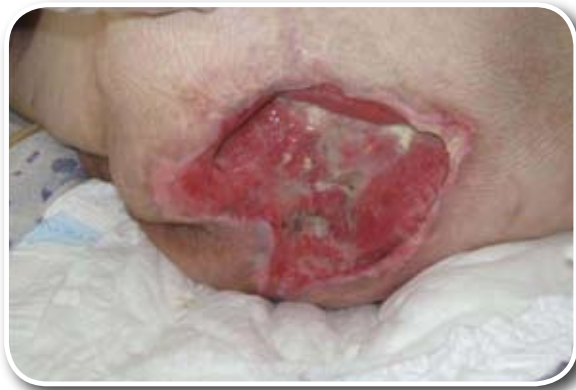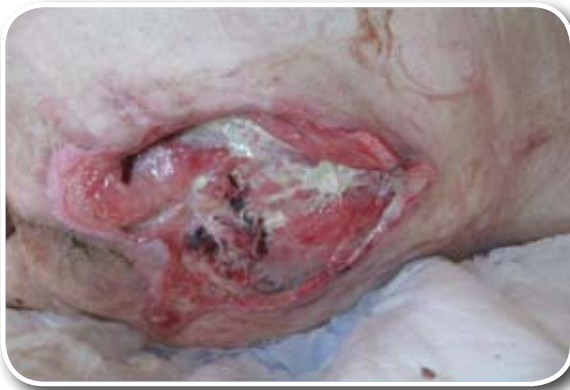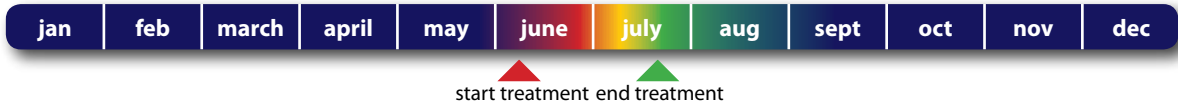CaseStudy Sacral pressure ulcer

This is a 63 year old female suffering from sacral pressure ulcer.

Comorbidities: Malnutrition, Diabetes, PAD,PVD, Hypertension, Albumin 3.0

The wound received sharp debridement and then was placed on the Genadyne A4 NPWT system using AMD gauze dressing and flat drain. Drainage was shown to be serosanguinous in nature and produced approximately 50 cc per day. The dressings were changed every 72 hours and the patient had no complaints of pain. The wound developed a nice bed of granulation tissue to the point NPWT was discontinued and the wound was covered with a traditional dressing protecting the new epithelium.



A more detail and complete list of case studies can be presented upon request.

Genadyne Biotechnologies

65 Watermill Lane | Great Neck | NY 11021 | U.S.A

Tel.: +1-516-487-8787 Fax: +1-516-487-7878

E-mail: npwt@genadyne.com | www.genadyne.com

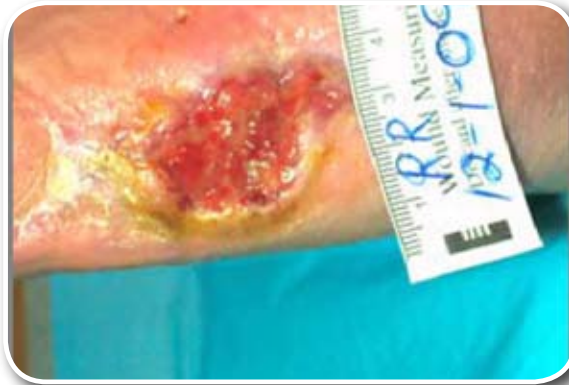
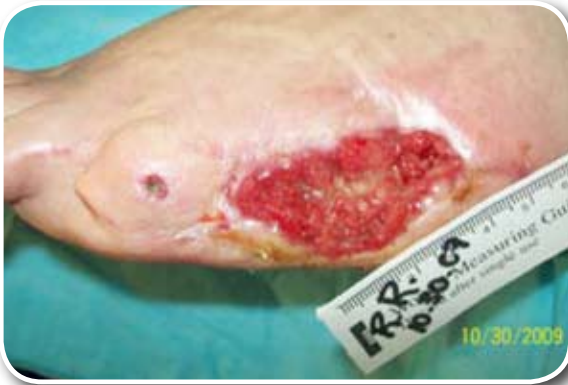
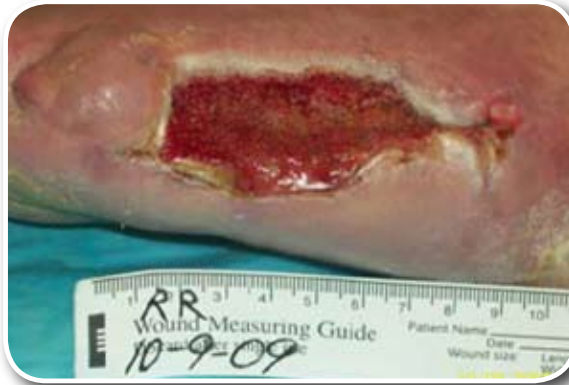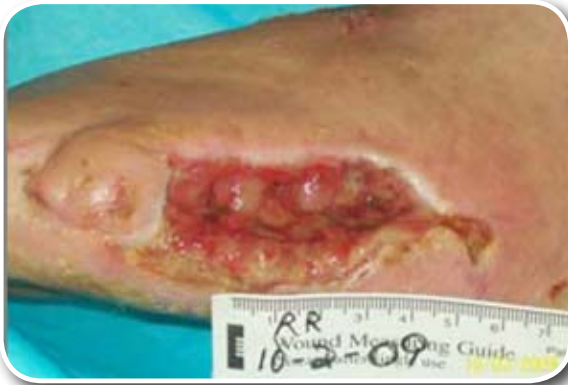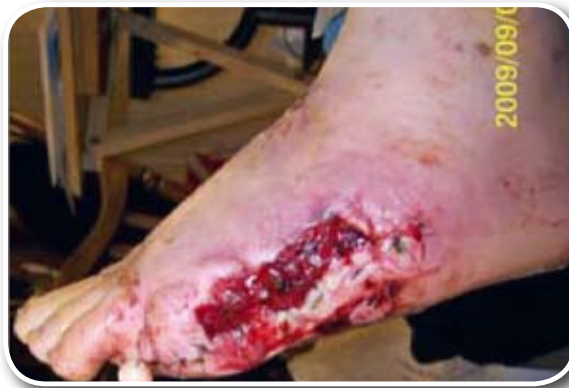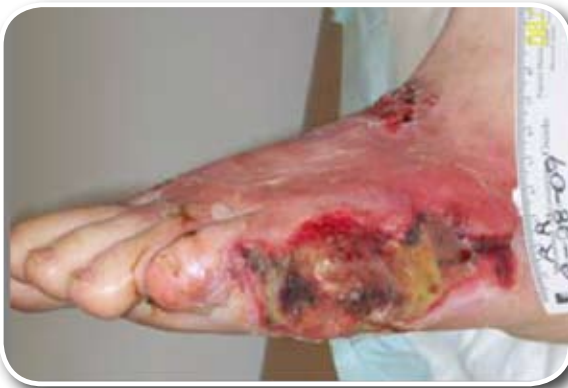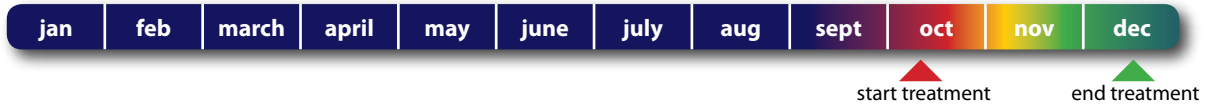CaseStudy

XLR8 and foam to treat a postoperative metatarsal amputation defect

Michael S. DO, The Wound Healing Center Indianapolis, IN / Miller Gerry Hash DPM, Bloomington, IN

Patient is a 48 year old male who underwent amputation of the 5th metatarsal due to progression of a diabetic foot ulcer with osteomyelitis. Expert surgical intervention resulted in a large lateral foot tissue defect. Therapy was commenced using the Genadyne XLR8 pump and XLR8 foam at 80mmHg. Using this therapy, rapid improvements were noted with an excellent progress.



A more detail and complete list of case studies can be presented upon request.

Genadyne Biotechnologies

65 Watermill Lane | Great Neck | NY 11021 | U.S.A

Tel.: +1-516-487-8787 Fax: +1-516-487-7878

E-mail: npwt@genadyne.com | www.genadyne.com

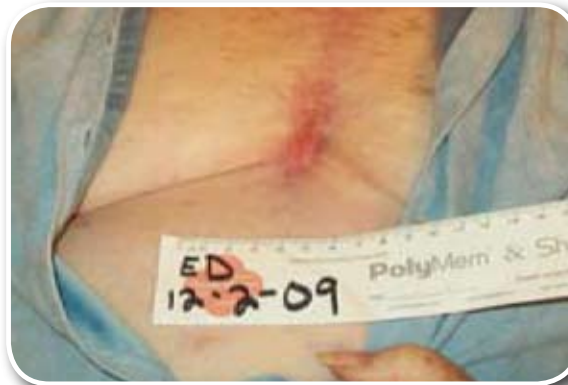
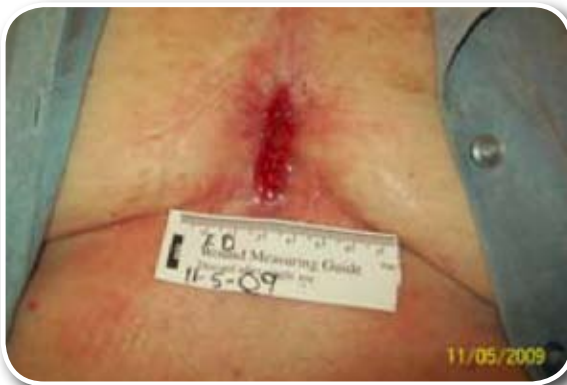
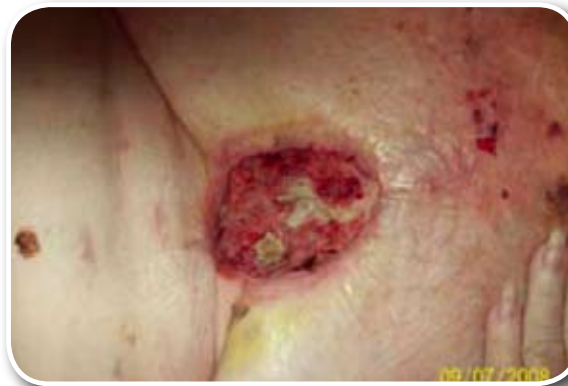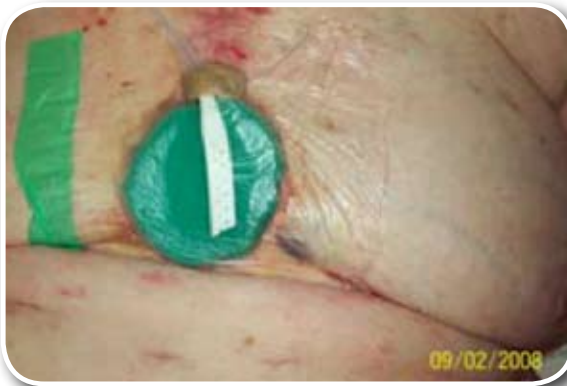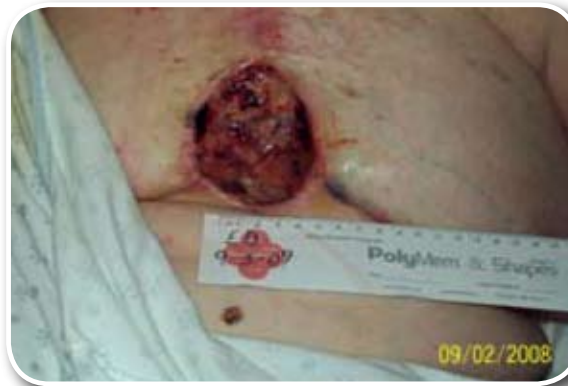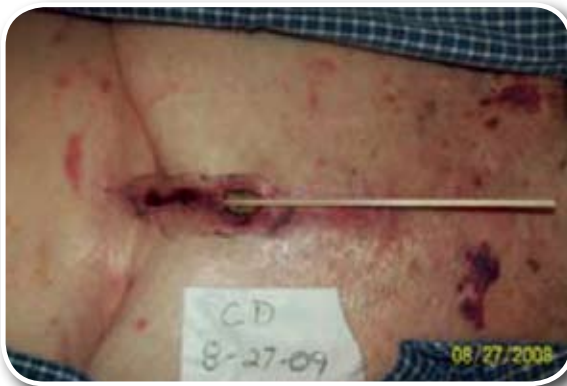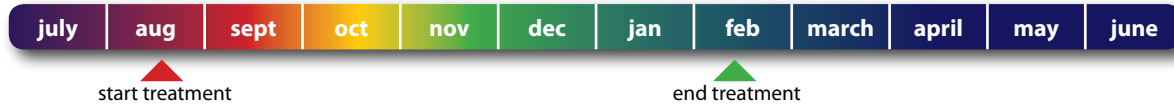CaseStudy

XLR8 and foam foam to treat a to treat a Large, Sternal Wound Dehiscence

Michael S. DO, The Wound Healing Center Indianapolis, IN / Miller Cynthia Peebles RN D.O.N., Becky Beck RN Avon, IN

Patient is a 76 yo female who underwent coronary bypass grafting X 4. Shortly after surgery, she began having drainage from the wound through three separate defects (Picture 1). Her Surgeon and Infectious Disease physicians elected to not open or debride the wound and commenced Negative Pressure Wound Therapy by placing the KCI black foam on her skin covering the three skin defects. She was transferred to the nursing care facility where she was evaluated. Debridement encompassing the involved skin and the wound base and sides was performed (Picture 2). Therapy was commenced using the Genadyne XLR8 pump and XLR8 foam at 80mmHg (Picture 3). Using this therapy, rapid improvements were noted with an excellent final appearance noted.



A more detail and complete list of case studies can be presented upon request.

Genadyne Biotechnologies

65 Watermill Lane | Great Neck | NY 11021 | U.S.A

Tel.: +1-516-487-8787 Fax: +1-516-487-7878

E-mail: npwt@genadyne.com | www.genadyne.com



CaseStudy

Surgical Dehiscence 3 month open dehiscence s/p Lumbar Laminectomy

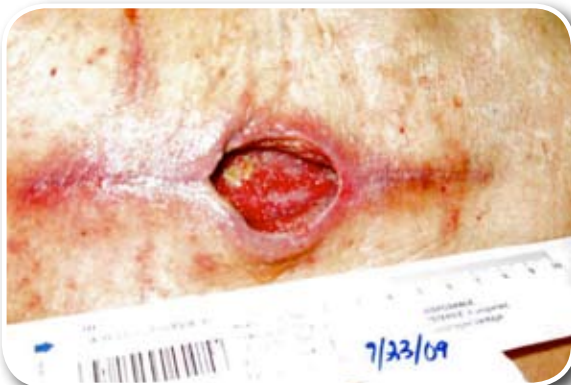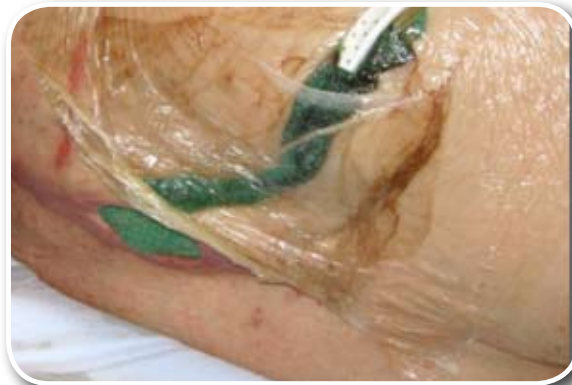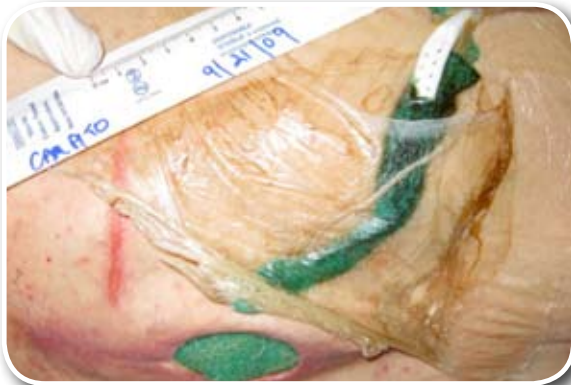
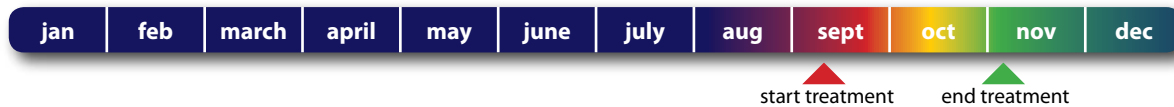Comorbidities: Severe Malnutrition, CAD, Small Bowel Resection. **Wound dimensions:** 4x2x2 with 7 cm tunneling distally and 6.5 cm tunneling superiorly and 3 cm undermining laterally. **Prior Care:** Moist to dry dressings, calcium alginates, silver hydrogel to no avail. **Laboratory:** Albumin 1.9 Poor eating habits. No enteral or TPN administered.

This 79 year old Caucasian male was admitted to the hospital for a small bowel resection. Upon arrival and assessment, his prior lumbar laminectomy incision site was found to be dehisced. He had no care-givers in the home and was found to be dehydrated as well as malnourished. Traditional wound care was applied at time of admission to no avail. Albeit the patients albumin was below therapeutic values, and protein supplements were added to his p.o. diet, his appetite remained substandard and surgery was consulted for possible peg tube placement. The surgeons declined to do surgery due to his hemodynamic instability and his combativeness.

The decision was made to start NPWT via Genadyne XLR8 at -100 mmHg and a foam dressing with JP drain as conduit. Initial wound assessment showed 70% thick, sticky yellow slough in the wound bed but the wound edges remained unremarkable. The wound was cleaned with normal saline and gauze and the NPWT dressing was applied. Initial dressing change was performed at 48 hours revealing a decrease in slough to 20%, the wound was pink in appearance and approximately 50 cc's of serosanguinous drainage was in the collection canister. A new dressing was applied with orders to change in another 48 hours.

The second dressing change occurred in 48 hours with no slough remaining in the wound bed, tissue was pink and beginning to granulate. The undermining decreased 2 mm and the tunneling decreased 0.5 cm in depth. Again, with less than adequate albumin level the wound was progressing. The dressing was reapplied and continued at -100 mmHg. Unfortunately, the patient succumbed to an anterior wall myocardial infarction one day later.

Conclusion: Considering the low albumin, and the co-morbidities, the wound was debrided, and started to heal both with the tunneling and undermining involved by the use of NPWT and the Genadyne XLR8 Negative Pressure Wound Therapy System.



A more detail and complete list of case studies can be presented upon request.

Genadyne Biotechnologies
65 Watermill Lane | Great Neck | NY 11021 | U.S.A
Tel.: +1-516-487-8787 Fax: +1-516-487-7878
E-mail: npwt@genadyne.com | www.genadyne.com

